

Pineapple Juice as a contrast agent in MRCP Exams

D.Selvaraj¹, D.Arulkumar², D.Dhinakaran³

¹ Professor, Electronics and Communication Engg., Panimalar Engineering College, Tamilnadu, India

² Assistant Professor(G-I), Electronics and Commn., Engg., Panimalar Institute of Technology, TN, India

³ Assistant Professor, Computer Science and Engg., Peri Institute of Technology, Tamilnadu, India

ABSTRACT

This paper deals with the images obtained using pineapple juice as a oral contrast agent compared to a manufactured standard iron oxide based contrast, chelate gadolinium-gadopentetate dimeglumine in Magnetic Resonance Cholangiopancreatography (MRCP). The research was done with 30 patients submitted to MRCP exams. On first day, a manufactured iron oxide based contrast (A) was offered and on the second day, pineapple juice (contrast B) was given to patients. Two radiologists R1 and R2 evaluated the images, classified them by giving the score (maximum of 4). On evaluating images developed by contrast A, R1 furnished an average score of 3.6 and R2 provided 3.47. similarly, On evaluating images developed by contrast B, R1 provided an average score of 3.54 and R2 provided 3.42. Thus, pineapple juice can be an alternative contrast agent in MRCP.

Keyword : - Pineapple contrast agent, iron oxide contrast, magnetic resonance cholangiopancreatography

1. INTRODUCTION

Magnetic Resonance Cholangiopancreatography (MRCP) exams make use of a negative contrast to identify and visualize organs such as pancreas and gallbladder. In the images, contrast agents can avoid the overlapping of these organs. The procedure is useful for detection of pancreatitis, cholelithiasis, biliary sludge, pseudo pancreatic cysts, tumors and others. Images acquired by magnetic resonance with natural contrasts are very similar to those acquired with manufactured ones [2]. For a juice to be effective as contrast agent in MRCP exams, some features are required [3], besides acting to reduce signal intensity from the stomach and duodenum and, improving bile duct and gallbladder views. Although there are papers about the use of juices as MRCP contrast agents [4], it was not found publications about standardization procedure and administration protocol of the juices [5]. Image evaluation is achieved from several ways in clinics and hospitals by means of medical analysis or using some computational tool. These can help to identify lesions, tumors or tissue being examined. Image evaluation can present inherent limitation due to the technique employed or analysis made by different personnel and equipment.

Since there is a great amount of subjectivity on the assessment of the acquired images by medical teams, depending on the previous experience of each evaluator, there is an opportunity to explore the use of Image J free software in order to produce a new quantitative analysis of the images and to compare them to medical evaluation. Thus, the main objective of this study was to assess quality of MRCP images, obtained with the administration of pineapple juice and a manufactured iron oxide based contrast employed as negative oral contrast agents, by means of medical evaluation and with the use of Image J software.

2. MATERIALS AND METHODS

A. Contrast Agents

A natural juice obtained from pineapple was employed as contrast agent, a rich source of bromelain. The manufactured standard iron oxide based contrast, chelate gadolinium-gadopentetate dimeglumine used specifically for MCRP exams.

B. MRCP Exam Protocol

As patients would need a medical report, the exam was started (first day) after the ingestion of the manufactured iron oxide based contrast (referred as A) with the sequence of full abdomen, followed by MRCP. On the second day, after the ingestion of pineapple juice (referred as contrast B), the MRCP sequence was also performed. Doctors supported the patients in the days of exams, but the type of contrast administered each day was kept secret. Thus, the study was double-blind and prospective.

The images were acquired with a 1.5T MRI system. The usual MRCP acquisition protocol was used: localizer (LOC) in 3 orthogonal planes (PL) following single-shot (SS), fast spin echo (FSE) in apnea (LOC 3 PL SSFSE Apnea); radial colangio and axial lava T1 without fat for the two days of exams.

C. Patient Selection

The selection of patients was made at the Government Hospital (GH), Chennai. For patient preparation, it was determined 3 hours of absolute fast. On the first day, when the patient arrived at the clinic, he/she was directed to the preparation room, the fasting time was confirmed and the manufactured contrast (A) was fractionated in 2 doses of 100 mL, one dose was given after the patient responded to the anamnesis, and another was given 10 minutes later. The anamnesis contained anthropometric data, history of allergy, use of medicines, pre-existing diseases (as diabetes and hepatitis), surgeries, etc. In case of a diabetic patient, glucose measurement in blood was performed before and after ingestion of contrasts. On the second day, the procedure was similar, only changing the contrast, i. pineapple juice (B) in 2 doses of 100 mL was started.

Patients who participated met the following criteria: age between 20 and 55 years for both genders, need to perform exams of MRCP and present pancreaticobiliary disease and/or alteration in liver ducts [6, 7] being in treatment or follow-up in the referred hospital and, ingest the contrast agents orally and accomplish fasting of 3 hours in the 2 days of the exams. Also, patients should lie down, not have claustrophobia nor hearing difficulties.

D. Medical images analysis

For the analysis of images, there was the collaboration of 2 radiologists identified as R1 and R2, both with large experience in image diagnosis of more than 20 years.

To analyze the effects of contrasts, scores 1-4 were used, having as reference the action of the contrast in places where it must make effect (stomach and duodenum). Score 1 means that there is a hyper intensity of the stomach and duodenum signals, thus it is not possible to evaluate these structures. Score 2: evaluation takes place partly when it is possible to visualize the structures. Score 3: the hyper intensity of the signal does not hinder the analysis of structures. Score 4: there is no signal hyper intensity between the stomach and duodenum, which makes clearer the MRCP exam. The evaluation of the image quality by doctors followed the filling of a patient individual form which contained: image quality classification for contrasts A and B as excellent, good, fair and poor; if the acquired image for contrasts A and B could replace each other; and if the contrasts were suitable and efficient for issuing a medical report [8].

Also, a new quantitative evaluation method based on Image J free software, 16-bits version, was employed [1] and it can furnish the intensity of pixels against distance of a chosen area of an image. By taking a section of interest from the image, one can limit the anatomical region of the structure to be analyzed. After, the selected area (with x and y values) is transferred to an Excel file and a plot is produced with gray levels (pixel intensities) against distance (width of the bile duct region for this study) in mm [9].

3. RESULTS AND DISCUSSION

Altogether 30 patients were participated in the exams. The implemented MRCP protocol allowed 720 (30x2x12) acquisitions of sequences of radial colangio for all patients in the two days of exams.

A. Medical Evaluation

For the assessment of medical images, each evaluator chose between the sequences of images, two of them, one for each type of contrast. The images had to show the region of the biliary tract with quality and reduce the signal of the stomach and duodenum allowing a medical report. Table 1 shows the frequency of medical scores attributed by evaluators R1 and R2. For score 1, no image was chosen. For score 2, on the 1st day R1 evaluated 1 patient and R2 1, on the 2nd day 2 were evaluated by R1 and 1 by R2. For score 3, on the 1st day 12 were for R1 and 11 for R2, and on the 2nd day 12 were for R1 and 13 for R2. Finally, for value 4, on the 1st day they were 17 (R1) and 18 (R2), and on the 2nd day evaluations were 18 by R1 and 16 by R2.

Table 1 Image Scores for Contrasts A and B as Attributed by Evaluators 1 and 2

Scores	Evaluator (R1)		Evaluator (R2)	
	Contrast A	Contrast B	Contrast A	Contrast B
1	0	0	0	0
2	1	2	1	1
3	12	12	11	13
4	17	16	18	16
Total	30	30	30	30

Kappa analysis was performed to evaluate the correlation between assessments on the 2 days of tests. For the 1st day, the coefficient was 0.521, indicating a moderate agreement between evaluators. The 95% confidence interval for the Kappa coefficient ranged from 0.363 to 0.679. On the 2nd day the coefficient stood at 0.674, also indicating a moderate concordance for two doctors. The 95% confidence interval ranged from 0.521 to 0.828.

B. Image J Analysis

Figure 1 (a and b) shows an example of high standard images as assessed by R1 and R2. Both images received score 4 from both doctors on 2 days. The images were acquired with administration of contrasts A (manufactured) and B (pineapple juice) for the radial colangio sequence of patient F16 (F=female, number=identification). It is seen, similarly, in both images that the contrasts canceled the stomach and duodenum signals, showing the completion of the bile duct. Image J software was employed with Figure 1 (a and b) to obtain an image quantitative analysis by taking a chosen section of the bile duct (lower third since it is of great interest for image quality). The arrows indicate the chosen areas of the duct lower third of about 60.58mm (width) x 3.22mm (height) as indicated by doctors for both contrasts to build Figure 1c. Figure 1c shows gray levels (pixels intensity) against distance where 4 anatomical regions are shown for both contrasts. Arrow 1 indicates the duodenum, 2 the bile duct, 3 the pancreatic tract and, 4 the pancreas head.

Gray levels of contrast A had values from 31.2 to 92 for region 1, 48.8 to 723 for region 2, 40.8 to 352.4 for region 3 and, 28.2 to 67.6 for region 4. Considering contrast B, values obtained were from 26.8 to 60.4 (region 1), 42.6 to a 668.8 (region 2), 30.1 to 312.4 (region 3) and, 30.1 to 190.4 (region 4). For image quality, the duodenum region should be darker (hypo signal) and the bile duct should be brighter (hyper signal).

Figure 2 shows average curves for scores 2, 3 and 4 obtained for female (F) and male (M) patients with contrast A (as Table 1). Figure 2a was built for evaluator R1 and Figure 2b for R2. The mean intensities of each region from curves per score were calculated and for region 1 (0 up to 22.39 mm, duodenum) (Figure 2a-R1) are: 187.1 (score 2), 91.9 (score 3), 44.4 (score 4); region 2 (26.13 up to 34.9 mm, bile duct): 351.2 (score 2), 159.9 (score 3), 169.8 (score 4); region 3-4 (30.47 up to 69.51 mm, pancreatic tract and pancreas head): 87.9 (score 2), 68.6 (score3), 51 (score 4). As for evaluator R2 (Figure 2b), the values for region 1 are: 221.3 (score 2), 63.8 (score 3), 46.5 (score 4); region 2: 321.9 (score 2), 143.8 (score 3), 189.1 (score 4); region 3-4: 161 (score 2), 51 (score 3), 51.9 (score 4).

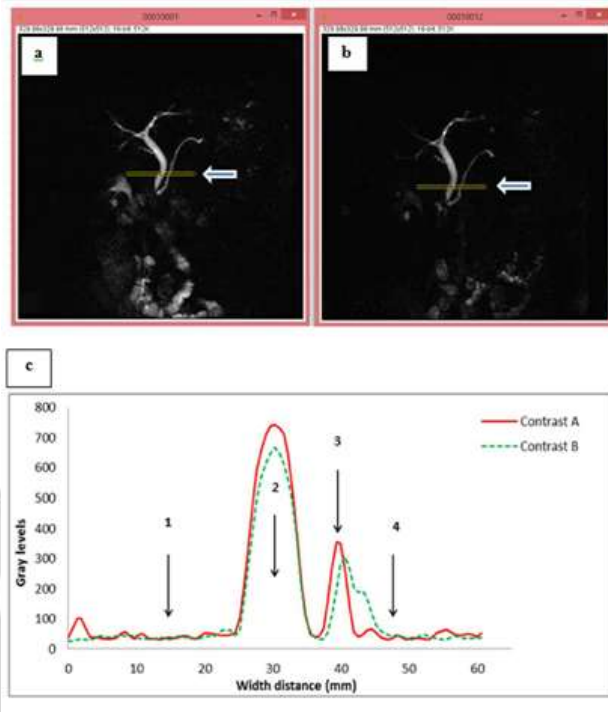
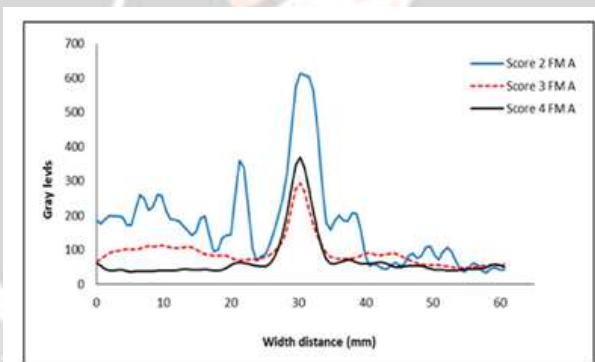
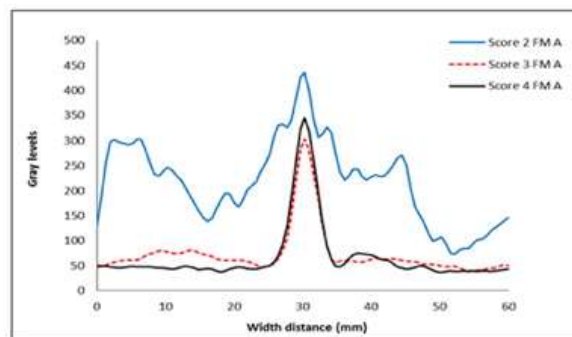


Figure 1 Images of the colangio radial sequence of patient F16 that received same score (4), where: (a) obtained with contrast A and, (b) contrast B. (c) Curves of gray levels against distance for both contrasts as obtained with Image J, with arrows indicating regions of (1) duodenum, (2) bile duct, (3) pancreatic tract and, (4) pancreas head.



(a)



(b)

Figure 2 Mean curves for all patients (females and males) for each score with contrast A (as Table 1). a) Evaluator R1: Score 2 (1 patient), 3 (12), 4 (17); b) Evaluator R2: Score 2 (1), 3 (11), 4 (18).

Figure 3 shows average curves for scores 2, 3 and 4 obtained for female (F) and male (M) patients with contrast B (as Table 1). Figure 3a was built for evaluator R1 and Figure 3b for R2. The mean intensities of each region from curves per score were calculated and for region 1-duodenum (Figure 3a-R1) are: 178.8 (score 2), 71.9 (score 3), 42.6 (score 4); region 2: 433.5 (score 2), 151.9 (score 3), 171.8 (score 4); region 3-4: 141.2 (score 2), 71.2 (score 3), 51.9 (score 4). As for evaluator R2 (Figure 3b), the values for region 1 are: 189.3 (score 2), 51.9 (score 3), 39.4 (score 4); region 2: 343.7 (score 2), 132.5 (score 3), 169 (score 4); region 3-4: 162.1 (score 2), 56 (score 3), 57.7 (score 4).

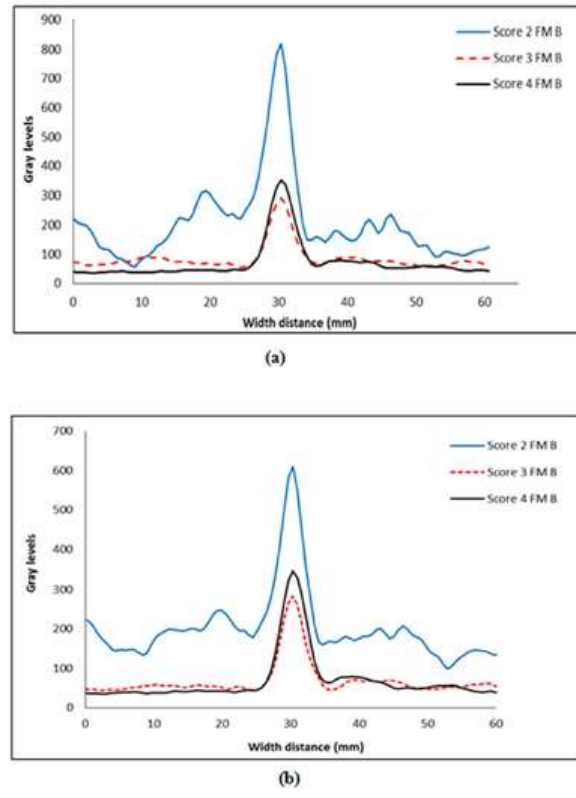


Figure 3 Mean curves for all patients (females and males) for each score with contrast B (as Table 2). a) Evaluator R1: Score 2 (2 patients), 3 (12), 4 (16) and b) Evaluator R2: Score 2 (1), 3 (13), 4 (16).

Comparing mean curves with scores 3 and 4, a correlation coefficient of 0.970 is obtained between them for R1 and 0.983 for R2, showing very little quantitative difference between scores 3 and 4 for each evaluator, according to Image J software.

4. CONCLUSION

To replace a manufactured contrast agent in MRCP, a juice must reduce signal strength between stomach and duodenum, being able to produce a medical report with diagnostic quality. By means of a proposed and tested protocol, pineapple juice showed a similar action of a manufactured iron oxide based contrast. For radiologists, the effectiveness of natural contrast was $\geq 94.6\%$, and for the manufactured one was equal to 96.2% , since both darkened the signal from stomach and duodenum and provided appropriate conditions for a MRCP quality medical report. pineapple juice can provide a reduced fasting time, being compatible for exams at different times and at any time of the day, and in several age groups (infants, children, adults and elderly). Patients with difficulty to make a long fast (as for diabetes or other diseases) can benefit from the natural agent, since it does not cause collateral effects and/or discomfort. Thus, pineapple juice is an alternative to be used as contrast agent, particularly for patients with hepatic and/or gastric changes, besides being inexpensive.

5. REFERENCES

- [1]. Juliana Avila Duarte, Alvaro Porto Alegre Furtado, Claudio Augusto Marroni, "Use of pineapple juice with gadopentetate dimeglumine as a negative oral contrast for magnetic resonance cholangiopancreatography: a multicentric study", *Abdominal Imaging*, 2012, Vol. 37, PP. 447-456.
- [2]. *Magnetic Resonance Imaging Clinics of North America*, volume 26, pp.433-448
- [3]. Xiao B, Zhang, XM. Magnetic resonance imaging for acute pancreatitis. *World Radiol.* 2010; 2(8): 298- 308.
- [4]. Fraga TC, Araujo DB, Sanchez TA, Elias J Jr, Carneiro AAO, Oliveira RB, et al. Euterpe olerácea (açai) as an alternative oral contrast agent in mri of the gastrointestinal system: preliminar results. *Magn Reson Imag.* 2004; 22: 389-93.
- [5]. Chu ZQ, Ji Q, Zhang JL. Orally administred lemon/orange juice improved MRCP imaging of pancreatic ducts. *Abdom Imag.* 2010; 35(3): 367- 71
- [6]. Fukukura Y, Takumi K, Higashi M, Shinchi H, Kamimura K, Yoneyama K, et al. Contrast- enhanced CT and diffusion- weighted MR imaging: Perfomance as a prognostic fator in patients with pancreatic ductal adenocarcinoma. *Eur Radiol.* 2014; (83): 612-19
- [7]. Pinheiro YLS, Costa RZV, Pinho KEP, Ferreira RR, Schuindt SM. Effects of iodinated contrast agent, xylocaine and gadolinium concentration on the signal emitted in magnetic resonance arthrography: a samples study. *Radiol Brasil.* 2015; 48(2): 69-73.
- [8]. Girometti R, Brondani G, Cereser L, Como G, Pin MD, Bazzocchi M, et al. Post-cholecystectomy syndrome: spectrum of biliary findings at magnetic resonance cholangiopancreatography. *The British Radiol.* 2010; 83:351-361.
- [9]. Westbrook C, Roth CK, Talbot J. *MRI in practice.* 4th ed. Wiley Blackwell; 2011

